

ORIGINAL ARTICLE

Identification and Importance of Brown Adipose Tissue in Adult Humans

Aaron M. Cypess, M.D., Ph.D., M.M.Sc., Sanaz Lehman, M.B., B.S.,
Gethin Williams, M.B., B.S., Ph.D., Ilan Tal, Ph.D., Dean Rodman, M.D.,
Allison B. Goldfine, M.D., Frank C. Kuo, M.D., Ph.D., Edwin L. Palmer, M.D.,
Yu-Hua Tseng, Ph.D., Alessandro Doria, M.D., Ph.D., M.P.H.,
Gerald M. Kolodny, M.D., and C. Ronald Kahn, M.D.

ABSTRACT

BACKGROUND

Obesity results from an imbalance between energy intake and expenditure. In rodents and newborn humans, brown adipose tissue helps regulate energy expenditure by thermogenesis mediated by the expression of uncoupling protein 1 (UCP1), but brown adipose tissue has been considered to have no physiologic relevance in adult humans.

METHODS

We analyzed 3640 consecutive ^{18}F -fluorodeoxyglucose (^{18}F -FDG) positron-emission tomographic and computed tomographic (PET-CT) scans performed for various diagnostic reasons in 1972 patients for the presence of substantial depots of putative brown adipose tissue. Such depots were defined as collections of tissue that were more than 4 mm in diameter, had the density of adipose tissue according to CT, and had maximal standardized uptake values of ^{18}F -FDG of at least 2.0 g per milliliter, indicating high metabolic activity. Clinical indexes were recorded and compared with those of date-matched controls. Immunostaining for UCP1 was performed on biopsy specimens from the neck and supraclavicular regions in patients undergoing surgery.

RESULTS

Substantial depots of brown adipose tissue were identified by PET-CT in a region extending from the anterior neck to the thorax. Tissue from this region had UCP1-immunopositive, multilocular adipocytes indicating brown adipose tissue. Positive scans were seen in 76 of 1013 women (7.5%) and 30 of 959 men (3.1%), corresponding to a female:male ratio greater than 2:1 ($P < 0.001$). Women also had a greater mass of brown adipose tissue and higher ^{18}F -FDG uptake activity. The probability of the detection of brown adipose tissue was inversely correlated with years of age ($P < 0.001$), outdoor temperature at the time of the scan ($P = 0.02$), beta-blocker use ($P < 0.001$), and among older patients, body-mass index ($P = 0.007$).

CONCLUSIONS

Defined regions of functionally active brown adipose tissue are present in adult humans, are more frequent in women than in men, and may be quantified noninvasively with the use of ^{18}F -FDG PET-CT. Most important, the amount of brown adipose tissue is inversely correlated with body-mass index, especially in older people, suggesting a potential role of brown adipose tissue in adult human metabolism.

From the Research Division, Joslin Diabetes Center (A.M.C., A.B.G., Y.-H.T., A.D., C.R.K.); the Division of Nuclear Medicine, Beth Israel Deaconess Medical Center (S.L., G.W., I.T., D.R., G.M.K.); the Department of Pathology, Brigham and Women's Hospital (F.C.K.); the Division of Nuclear Medicine, Massachusetts General Hospital (E.L.P.); and Harvard Medical School (A.M.C., S.L., G.W., I.T., D.R., A.B.G., F.C.K., E.L.P., Y.-H.T., A.D., G.M.K., C.R.K.) — all in Boston. Address reprint requests to Dr. Kahn at the Section on Obesity and Hormone Action, Joslin Diabetes Center, 1 Joslin Pl., Boston, MA 02215, or at c.ronald.kahn@joslin.harvard.edu.

N Engl J Med 2009;360:1509-17.

Copyright © 2009 Massachusetts Medical Society.

OBESITY RESULTS FROM AN IMBALANCE between energy intake and expenditure.^{1,2} The adipose-tissue pool in mammals is composed of at least two functionally different types of fat: white and brown. White adipose tissue is the primary site of energy storage and of release of hormones and cytokines that modulate whole-body metabolism and insulin resistance.³⁻⁶ Excess accumulation of white adipose tissue causes obesity. Brown adipose tissue, on the other hand, is important for both basal and inducible energy expenditure in the form of thermogenesis mediated by the expression of the tissue-specific uncoupling protein 1 (UCP1). Brown adipose tissue affects whole-body metabolism and may alter insulin sensitivity^{7,8} and modify susceptibility to weight gain.⁹

Brown adipose tissue is present in rodents throughout life. In humans, brown adipose tissue is found primarily in infants and young children, and it has been considered to be essentially nonexistent and without physiologic relevance in adults.¹⁰ However, estimates suggest that if it were present, as little as 50 g of maximally stimulated brown adipose tissue could account for up to 20% of daily energy expenditure in an adult human.¹¹ Despite its potential physiologic importance, methods to measure the mass and activity of brown adipose tissue in humans have been lacking. Recently, combined positron-emission tomography and computed tomography (PET-CT) has been used to identify adipose tissue with a high rate of uptake of ¹⁸F-fluorodeoxyglucose (¹⁸F-FDG) as putative brown adipose tissue.¹²⁻¹⁷ However, correlation of this tissue, detected with the use of PET-CT, with immunohistochemical evidence of UCP1 expression or metabolic state has been inconclusive.^{12-14,16-19} In this study, we analyze ¹⁸F-FDG PET-CT images in 1972 patients and present evidence for the presence of physiologically significant brown adipose tissue in adult humans.

METHODS

PATIENTS

This study followed institutional guidelines and was approved by the ethics committees of Beth Israel Deaconess Medical Center and Partners HealthCare, in Boston. Because only medical records and discarded material were examined, the consent of patients was not required. For immuno-

histochemical analysis of UCP1, adipose tissue from the neck and supraclavicular regions of 33 patients who previously had undergone surgical procedures at Partners HealthCare was identified with the use of the Harvard Medical School Shared Pathology Informatics Network. None of these 33 patients had undergone PET-CT scanning.

DATA COLLECTION

We analyzed 3640 consecutive ¹⁸F-FDG PET-CT whole-body scans performed on 1972 patients for a variety of diagnostic reasons at Beth Israel Deaconess Medical Center from August 2003 through May 2006. Data on age and sex were obtained for all patients. Data on height, weight, fasting plasma glucose level, medication use, diagnosis, and smoking history were obtained for all patients who had substantial amounts of brown adipose tissue according to PET-CT scans and for a control group consisting of two patients without detectable brown adipose tissue who underwent scanning on the same day as each patient with brown adipose tissue (see Table 1 in the Supplementary Appendix, available with the full text of this article at NEJM.org). Outdoor temperatures in Boston for the dates of scans were obtained from the U.S. Weather Service.

Routine histologic and immunohistochemical assays for UCP1 with the use of polyclonal anti-mouse UCP1 antibody (Santa Cruz Biotechnology) were performed on paraffin sections. PET-CT images were acquired with the use of a Discovery LS multidetector helical PET-CT scanner (GE Medical Systems).²⁰ In areas where uptake of ¹⁸F-FDG was identified by PET and the presence of fat was identified by CT, the maximal and mean standardized uptake values (SUVs), defined as the activity per milliliter within the region of interest divided by the injected dose in megabecquerels per gram of body weight, were determined. Calculations were performed with the use of OpenPACS and PET-CT Viewer shareware.²¹ Images from Massachusetts General Hospital were acquired in a similar manner.²²

STATISTICAL ANALYSIS

The data were analyzed with the use of SAS software, version 9.1, and VassarStats (<http://faculty.vassar.edu/lowry/VassarStats.html>). Normally distributed continuous variables were compared between study groups with the use of Student's t-test, and non-normally distributed continuous variables

were compared with the use of the Mann–Whitney U test. The roles of sex, age, body-mass index (BMI), smoking history, cancer diagnosis, and medication history as predictors of substantial brown adipose tissue were tested by logistic regression with the use of univariate and multivariate models. The patients were divided into groups corresponding to the upper, middle, and lower thirds of the values for age, BMI, and plasma glucose level; the significance of linear trends across the thirds was tested by assigning each participant the median value for the third and modeling this value as a continuous variable. Missing values for plasma glucose (in four patients) were assigned to the middle third. For medication and smoking history, a missing-value indicator was added to the model. Odds ratios and 95% confidence intervals were estimated as measures of the magnitude of the associations. The significance of interactions of BMI with age and sex was assessed by adding a cross-product term to the logistic-regression model. All P values presented are two-tailed, and values less than 0.05 are considered to indicate statistical significance.

RESULTS

RADIOLOGIC AND IMMUNOHISTOCHEMICAL EVALUATION OF BROWN ADIPOSE TISSUE

The use of PET–CT to investigate brown adipose tissue in humans began with a 67-year-old woman who was being evaluated for a right supradiaphragmatic tumor. Scanning with ^{18}F -FDG PET–CT revealed a tumor with the density of adipose tissue but with higher ^{18}F -FDG uptake than was typical for subcutaneous or visceral fat depots (see Fig. 1A through 1D in the Supplementary Appendix). Resection identified a brown-fat tumor (hibernoma) that was composed of characteristic polygonal cells with multilocular lipid droplets and central nuclei (Fig. 1E in the Supplementary Appendix) interspersed with typical white adipocytes containing large, single lipid droplets and peripheral nuclei. The identity of the cells as brown adipocytes was confirmed by immunohistochemical staining for UCP1 (Fig. 1F in the Supplementary Appendix). Review of the pathological features of cervical and supraclavicular tissue from 33 other patients who had undergone neck surgery revealed similar UCP1-positive brown adipose tissue mixed with white adipose tissue, a result suggesting that brown adipose tissue may also

be present in people without hibernomas²³ (Fig. 1A and 1B).

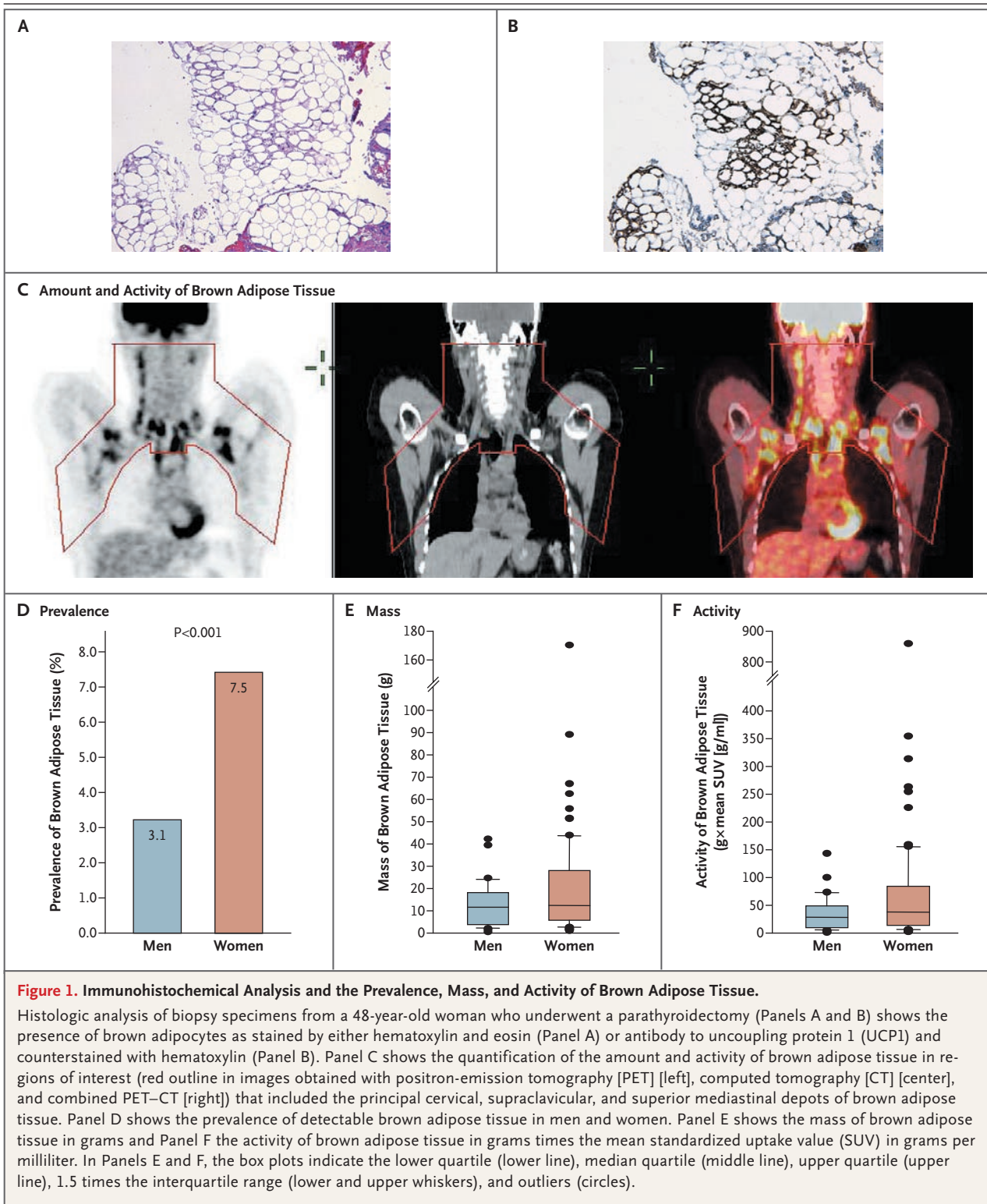
PREVALENCE, MASS, ACTIVITY, AND SEXUAL DIMORPHISM OF BROWN ADIPOSE TISSUE

In the analysis of ^{18}F -FDG PET–CT scans, brown adipose tissue was considered present if there were areas of tissue that were more than 4 mm in diameter, had the CT density of adipose tissue (–250 to –50 Hounsfield units), and had a maximal SUV of ^{18}F -FDG of at least 2.0 g per milliliter (Fig. 1C). This cutoff represented the lower boundary of activity in patients with detectable brown adipose tissue according to our previous study about the method of ^{18}F -FDG uptake,²⁰ and it was more than 2 SD above the maximal SUV seen in typical depots of white adipose tissue. According to these criteria, 106 of the 1972 patients (5.4%) had tissue that was identified by PET–CT as being consistent with brown adipose tissue, a result similar to the results of previous, smaller studies.^{12,14,17} The prevalence of detectable brown adipose tissue was higher in women (7.5% [76 of 1013]) than in men (3.1% [30 of 959, $P < 0.001$]) (female:male ratio, 2.4:1.0) (Fig. 1D).

The volume and activity of brown adipose tissue were quantified with PET–CT Viewer software²¹ in user-defined regions of interest in the cervical, supraclavicular, and superior mediastinal depots (Fig. 1C). On the assumption of a density of fat of 0.90 g per milliliter, as defined with the use of CT scanning,²⁴ the median amount of detectable brown adipose tissue in these areas was 11.6 g (range, 0.5 to 42.0) in men and 12.3 g (range, 1.1 to 170.0) in women (Fig. 1E). The median mass and activity of brown adipose tissue were similar in both sexes but were skewed to higher levels in women than in men, a result suggesting that women have a greater capacity to increase the mass and activity of their brown adipose tissue (Fig. 1E and 1F).

ANATOMICAL DISTRIBUTION OF BROWN ADIPOSE TISSUE

The most common location for brown adipose tissue that was detectable in adults by PET–CT was the cervical–supraclavicular depot, in a distinct fascial plane in the ventral neck, superficial and lateral to the sternocleidomastoid muscles. In patients with high ^{18}F -FDG uptake (Fig. 1C), the distribution of sites with ^{18}F -FDG-avid fat extended inferiorly between the subscapularis and pectora-



lis muscles, posterior to the brachial plexus and proceeding through thoracic and abdominal paraspinal sites, with little perinephric activity.

RELATION BETWEEN DETECTION OF BROWN ADIPOSE TISSUE AND OUTDOOR TEMPERATURE

Considerable variation in ^{18}F -FDG uptake by the same depot of brown adipose tissue in the same patient was seen over time. Previous studies have suggested that uptake of ^{18}F -FDG by adipose tissue may decrease rapidly in response to increased outdoor temperature,¹⁸ anxiolytic agents such as benzodiazepines,²⁵ sympathetic blockade by propranolol,²⁶ and dietary intervention.²⁰ The long-term effect of outdoor temperature on brown adipose tissue was estimated in the present study by reviewing the dates of PET-CT scans in patients with detectable brown adipose tissue as compared with the dates of the scans in all patients. For patients with detectable brown adipose tissue, the dates on which the activity of the tissue was maximal were determined, and the mean outdoor temperature in Boston for the month when the activity was maximal was obtained from the U.S. Weather Service. The frequency of maximal activity was highest in the winter, lower in the spring and fall, and lowest in the summer ($P=0.03$) (Fig. 2A in the Supplementary Appendix). The association between maximal activity of brown adipose tissue and mean monthly temperature was evaluated by logistic regression with sex and age as covariates (Fig. 2A). Overall, the probability of maximal activity decreased with increasing outdoor temperature ($P=0.02$). Furthermore, at every temperature, the probability of detection of brown adipose tissue was significantly higher in women than in men ($P<0.001$), with no difference between the sexes in the slope of the regression lines.

ANTHROPOMETRIC AND METABOLIC PREDICTORS OF DETECTABLE BROWN ADIPOSE TISSUE

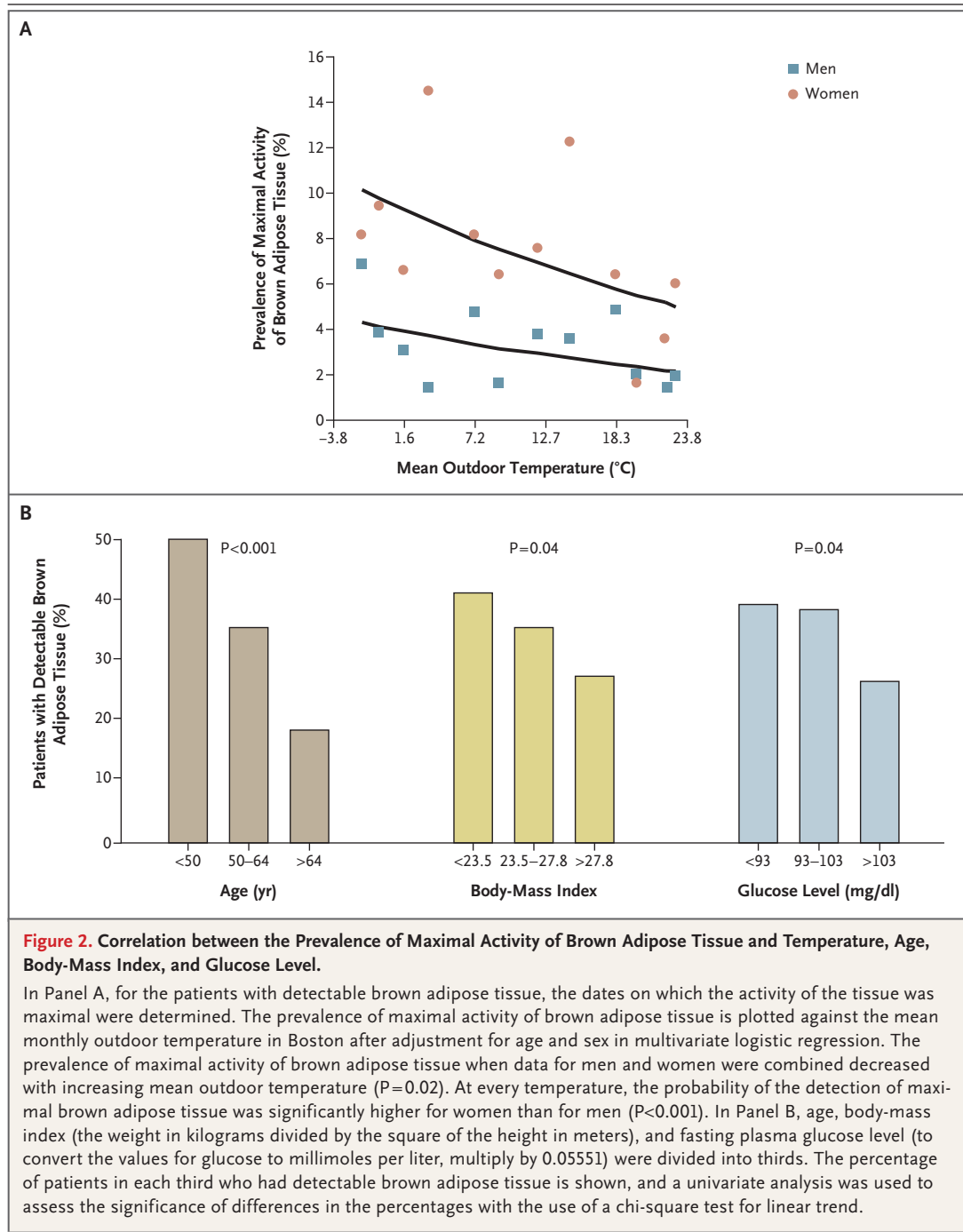
Additional predictors of a high mass of brown adipose tissue were estimated by examining the association of brown adipose tissue with age, BMI, fasting plasma glucose level, medication use, diagnosis, and smoking history in the 106 patients who had detectable brown adipose tissue and a sample of 204 date-matched control patients who did not have brown adipose tissue (Table 1 in the Supplementary Appendix). The age and sex distribution of patients without detectable brown adipose tissue was the same as that of the total

population of patients undergoing PET-CT (data not shown). In univariate analyses (Table 1), brown adipose tissue was most frequently detected in women ($P<0.001$), patients in the bottom third for age (younger than 50 years) ($P<0.001$), the least obese patients ($P=0.04$), those with lowest fasting plasma glucose levels ($P=0.04$) (Fig. 2B), those who were not using beta-blockers ($P<0.001$), and those who had never smoked ($P=0.02$) (Fig. 2B in the Supplementary Appendix).

In multivariate analyses, three predictors (sex, age, and beta-blocker use) remained significant. The likelihood of having substantial brown adipose tissue was greater in women than in men by a factor of approximately 3; the likelihood was lower among patients in the top third for age (above 64 years) than among those in the bottom third by a factor of approximately 3 and in those using beta-blockers than in those not using beta-blockers by a factor of approximately 10 (Table 1). BMI was not an independent predictor of the presence of brown adipose tissue in the multivariate analysis but became a significant predictor with increasing age (P for interaction = 0.008, after adjustment for sex and other predictors). The likelihood of having substantial brown adipose tissue was lower by a factor of six in patients older than 64 years of age who were in the top third for BMI than in those in the bottom third; the likelihood was intermediate for patients in the middle third (P for trend = 0.007) (Fig. 3 in the Supplementary Appendix). Thus, brown adipose tissue was found most frequently in young women and least frequently in older, overweight men and in patients receiving beta-blockers.

DISCUSSION

Many studies^{10,27,28} have indicated that brown adipose tissue in rodents has profound effects on body weight, energy balance, and glucose metabolism, and the presence of brown adipose tissue has been observed in adult humans under circumstances of long-term exposure to cold or of hyperadrenergic stimulation in pheochromocytoma.²⁹⁻³¹ However, there has been much debate as to whether brown adipose tissue normally exists in adult humans.^{11,32,33} Despite this debate, radiologic studies during the past several years have suggested that there are areas of adipose tissue with high ^{18}F -FDG uptake, presumably representing brown fat; the presence of such areas often creates con-



fusion in the interpretation of PET scans performed for the diagnosis of cancer.

In the present study involving 3640 ^{18}F -FDG PET-CT scans, we found substantial collections of brown adipose tissue in 7.5% of female patients and 3.1% of male patients. These findings should be considered minimal estimates of the

prevalence of brown adipose tissue, because the studies were done with the patients in the unstimulated state, and PET-CT identifies only brown adipose tissue with increased metabolic activity. Furthermore, dietary fuels, such as fatty acids, and some drugs can alter ^{18}F -FDG uptake,²⁰ and PET-CT can detect brown adipose tissue only

Table 1. Predictors of Detectable Brown Adipose Tissue Based on ¹⁸F-FDG PET-CT Scanning.*

Variable	Univariate Analysis		Multivariate Analysis	
	Odds Ratio (95% CI)	P Value	Odds Ratio (95% CI)	P Value
Sex				
Female vs. male	2.85 (1.72–4.72)	<0.001	3.07 (1.72–5.48)	<0.001
Years of age				
50–64 vs. <50	0.55 (0.31–0.96)		0.64 (0.33–1.21)	
>64 vs. <50	0.23 (0.12–0.43)	<0.001†	0.32 (0.15–0.67)	0.005†
Body-mass index‡				
23.5–27.8 vs. <23.5	0.81 (0.46–1.42)		1.32 (0.68–2.60)	
>27.8 vs. <23.5	0.54 (0.30–0.98)	0.04†	0.74 (0.38–1.44)	0.30†
Fasting plasma glucose level — mg/dl				
93–103 (5.2–5.7 mmol/liter) vs. <93	0.95 (0.54–1.67)		1.37 (0.70–2.68)	
>103 vs. <93	0.56 (0.31–1.01)	0.04†	0.97 (0.48–1.96)	0.77†
Cancer				
Lymphoma vs. no cancer	1.05 (0.41–2.67)		0.46 (0.14–1.46)	
Other cancers vs. no cancer	0.79 (0.31–2.02)	0.53§	0.47 (0.15–1.45)	0.40§
Smoking history				
Formerly vs. never	0.46 (0.26–0.81)		0.74 (0.38–1.44)	
Currently vs. never	0.58 (0.27–1.28)	0.02§	0.78 (0.32–1.93)	0.64§
Beta-blocker use				
Yes vs. no	0.06 (0.02–0.26)	<0.001	0.09 (0.02–0.38)	0.001
Benzodiazepine use				
Yes vs. no	1.74 (0.91–3.33)	0.09	0.99 (0.44–2.21)	0.98

* CI denotes confidence interval, ¹⁸F-FDG ¹⁸F-fluorodeoxyglucose, and PET-CT positron-emission tomography and computed tomography.

† The P value for trend across thirds with 1 df is given.

‡ The body-mass index is the weight in kilograms divided by the square of the height in meters.

§ The overall P value with 2 df is given.

if a sufficient number of brown adipocytes are aggregated in a given anatomical site. Indeed, with the use of other criteria, other, smaller PET-CT studies have reported detectable brown adipose tissue in 25%¹⁵ to more than 80%¹⁹ of patients, and one autopsy series identified brown adipose tissue in the necks of 26 of 31 patients (84%) over the age of 20 years.²³

Although we could not directly correlate the presence of ¹⁸F-FDG-avid adipose tissue detected by PET-CT with UCP1 immunohistochemical findings, several lines of evidence support the claim that this tissue is brown adipose tissue. First is the example of the patient with the brown-fat tumor, which formed a single, large mass of ¹⁸F-FDG-avid adipose tissue. Second, in patients with pheochromocytomas that hypersecrete cat-

echolamines, there is increased mass and activity of brown adipose tissue¹⁰ and increased ¹⁸F-FDG uptake into brown adipose tissue, which returns to normal after resection of the tumors.³⁴ Third, studies in rodents have shown that the avidity of interscapular brown adipose tissue for ¹⁸F-FDG is 50 times as great as the avidity of the surrounding depot of white adipose tissue.^{35,36} Finally, the present study identified UCP1-positive brown adipose tissue in a series of biopsy specimens taken from the same cervical and supraclavicular regions in which brown adipose tissue activity is most frequently observed by PET-CT. In these areas, it appears that the brown adipose tissue of human adults may consist of a mixture of white and brown adipocytes, as has been observed in some depots in the mouse.³⁷

PET-CT imaging emphasizes one particular region of active adult brown adipose tissue that lies in a fascial plane in the ventral neck and thorax bilaterally, distinct from the dorsal interscapular depot of brown adipose tissue observed in children²³ and rodents.³⁶ This difference in anatomical location may account for previous failures to identify brown adipose tissue in human adults.³⁸ On the basis of quantification within this principal depot alone, it is likely that more than half of all men and women have 10 g or more of brown adipose tissue. Given that 50 g of maximally stimulated brown adipose tissue could account for 20% of total resting energy expenditure,¹¹ our data suggest that brown adipose tissue is present in a substantial percentage of adults.

The distribution of white adipose tissue displays clear sexual dimorphism — men have greater amounts of intraabdominal white adipose tissue than do women, whereas women have more subcutaneous white adipose tissue in the thighs and hips than do men.³⁹ The depots of brown adipose tissue have similar distributions in both sexes, but the mass and activity of brown adipose tissue are greater in women than in men. Other factors appear to be associated with a higher mass of brown adipose tissue. Previous studies of biopsy specimens in northern Finland revealed more brown adipose tissue in outdoor workers than in indoor workers,²⁹ a result consistent with our observed correlation between the prevalence of detectable brown adipose tissue and outdoor temperature. Brown adipose tissue is essential for thermogenesis in human neonates¹⁰ but has been considered unnecessary in adults, who have higher basal metabolic rates and increased muscle mass for shivering. Previous PET-CT studies^{16,17} have also shown the inverse correlation between the prevalence of detectable brown adipose tissue and age that we observed in this study, with the greatest amount of detectable brown adipose tissue in younger adults. Our observations regarding beta-adrenergic blockers are consistent with the results of studies demonstrating that beta-blockers reduce ¹⁸F-FDG uptake in brown adipose tissue in the short term.²⁵ It is also possible that long-term use of beta-blockers reduces the mass or activity of brown adipose tissue, thus contributing to some of the weight gain associated with the use of beta-blockers.⁴⁰

There appears to be an interaction between

brown adipose tissue and obesity.^{12,14,17} In our study, univariate analysis showed an inverse correlation between the prevalence of detectable brown adipose tissue and BMI; after multivariate analysis, this correlation persisted among patients in the top third for age, a result suggesting that higher levels of brown adipose tissue may protect against age-related obesity. These results are consistent with earlier reports showing a similar but not significant trend toward lower BMI in people with functionally active brown adipose tissue.¹³ These observations are also consistent with murine studies showing that strains with higher levels of intermuscular brown adipose tissue are protected from diet-induced obesity and diabetes.^{9,37} Humans, like mice, have a range of metabolic rates. Thus, methods to stimulate generation and activation of brown adipose tissue might lead to new approaches to promoting weight loss and increasing insulin sensitivity.

In summary, in the present study, the use of ¹⁸F-FDG PET-CT shows that functional brown adipose tissue is prevalent in adult humans, with a significant female predominance. BMI is inversely correlated with the amount of brown adipose tissue, especially in older patients, a result suggesting a possible role of brown adipose tissue in protecting against obesity. We are hopeful that with increasing ability to measure the mass and activity of brown adipose tissue in humans *in vivo*, we will better understand its role in physiology and its potential as a therapeutic target in the treatment of obesity and other metabolic disorders.

Supported by the Clinical Investigator Training Program, Beth Israel Deaconess Medical Center—Harvard/MIT Health Sciences and Technology, in collaboration with Pfizer and Merck; grants from the National Institutes of Health (DK070722 and P30 DK46200 [to Dr. Tseng], DK33201 and DK55545 [to Dr. Kahn], and DK046200-16 [to Dr. Cypess]); and the Eli Lilly Foundation.

Dr. Cypess reports receiving grant support from the Eli Lilly Foundation and being the sole inventor on a pending patent application to use infrared thermography to monitor brown adipose tissue; Dr. Williams, receiving royalties from Bracco Pharma and having a pending patent regarding a method to prepare patients for PET-CT; Dr. Goldfine, receiving consulting fees from Tethys Bioscience and Merck and grant support from Eli Lilly and Daiichi Sankyo; Dr. Palmer, receiving consulting fees from Siemens Medical Systems; Dr. Tseng, receiving lecture fees from Genzyme and grant support from the Eli Lilly Foundation and the Tanita Healthy Weight Community; Dr. Kolodny, receiving grant support from GE Medical Systems and Sudbury Systems and royalties from Bracco Pharma; and Dr. Kahn, being an advisory board member for Sirtris, Plexxikon, FivePrime, and Dicerna, owning equity in GlaxoSmithKline, Plexxikon, and FivePrime, receiving lecture fees from Wyeth, Novartis, and Novo Nordisk, receiving grant support from the Eli Lilly Foundation, and having a pending

patent in the area of stimulating brown-fat growth with bone morphogenetic proteins. No other potential conflict of interest relevant to this article was reported.

We thank Lian Huang and Wendy Dasgupta for histochemical work; Eunice Torres, Doug Fairbanks, and Doris Dewing for

pathology library information services; Larry Barbaras and Andrew McMurray for information-technology support; and Arnold Barnett, Linda Ficociello, Andrzej Krolewski, and Peng Zhang for their assistance and guidance in statistical design and analysis.

REFERENCES

- Hossain P, Kowar B, El Nahas M. Obesity and diabetes in the developing world — a growing challenge. *N Engl J Med* 2007;356:213-5. [Erratum, *N Engl J Med* 2007;356:973.]
- Lazar MA. How obesity causes diabetes: not a tall tale. *Science* 2005;307:373-5.
- Aldhahi W, Hamdy O. Adipokines, inflammation, and the endothelium in diabetes. *Curr Diab Rep* 2003;3:293-8.
- Ronti T, Lupattelli G, Mannarino E. The endocrine function of adipose tissue: an update. *Clin Endocrinol (Oxf)* 2006;64:355-65.
- Farmer SR. Transcriptional control of adipocyte formation. *Cell Metab* 2006;4:263-73.
- Rosen ED, Spiegelman BM. Adipocytes as regulators of energy balance and glucose homeostasis. *Nature* 2006;444:847-53.
- Lowell BB, Susulic V, Hamann A, et al. Development of obesity in transgenic mice after genetic ablation of brown adipose tissue. *Nature* 1993;366:740-2.
- Yang X, Enerbäck S, Smith U. Reduced expression of FOXC2 and brown adipogenic genes in human subjects with insulin resistance. *Obes Res* 2003;11:1182-91.
- Almind K, Manieri M, Sivitz WI, Cinti S, Kahn CR. Ectopic brown adipose tissue in muscle provides a mechanism for differences in risk of metabolic syndrome in mice. *Proc Natl Acad Sci U S A* 2007;104:2366-71.
- Cannon B, Nedergaard J. Brown adipose tissue: function and physiological significance. *Physiol Rev* 2004;84:277-359.
- Rothwell NJ, Stock MJ. Luxusconsumption, diet-induced thermogenesis and brown fat: the case in favour. *Clin Sci (Lond)* 1983;64:19-23.
- Hany TF, Gharehpapagh E, Kamel EM, Buck A, Himms-Hagen J, von Schulthess GK. Brown adipose tissue: a factor to consider in symmetrical tracer uptake in the neck and upper chest region. *Eur J Nucl Med Mol Imaging* 2002;29:1393-8.
- Cohade C, Osman M, Pannu HK, Wahl RL. Uptake in supraclavicular area fat ("USA-Fat"): description on 18F-FDG PET/CT. *J Nucl Med* 2003;44:170-6.
- Cohade C, Mourtzikos KA, Wahl RL. "USA-Fat": prevalence is related to ambient outdoor temperature — evaluation with 18F-FDG PET/CT. *J Nucl Med* 2003;44:1267-70.
- Döbert N, Menzel C, Hamscho N, Wordehoff W, Kranert WT, Grünwald F. Atypical thoracic and supraclavicular FDG-uptake in patients with Hodgkin's and non-Hodgkin's lymphoma. *Q J Nucl Med Mol Imaging* 2004;48:33-8.
- Yeung HW, Grewal RK, Gonen M, Schöder H, Larson SM. Patterns of (18)F-FDG uptake in adipose tissue and muscle: a potential source of false-positives for PET. *J Nucl Med* 2003;44:1789-96.
- Truong MT, Erasmus JJ, Munden RF, et al. Focal FDG uptake in mediastinal brown fat mimicking malignancy: a potential pitfall resolved on PET/CT. *AJR Am J Roentgenol* 2004;183:1127-32.
- Garcia CA, Van Nostrand D, Majd M, et al. Benzodiazepine-resistant "brown fat" pattern in positron emission tomography: two case reports of resolution with temperature control. *Mol Imaging Biol* 2004;6:368-72.
- Rousseau C, Bourbouloux E, Champion L, et al. Brown fat in breast cancer patients: analysis of serial (18)F-FDG PET/CT scans. *Eur J Nucl Med Mol Imaging* 2006;33:785-91.
- Williams G, Kolodny GM. Method for decreasing uptake of 18F-FDG by hypermetabolic brown adipose tissue on PET. *AJR Am J Roentgenol* 2008;190:1406-9.
- Barbaras L, Tal I, Palmer MR, Parker JA, Kolodny GM. Shareware program for nuclear medicine and PET/CT PACS display and processing. *AJR Am J Roentgenol* 2007;188:W565-W568.
- Parodi K, Paganetti H, Shih HA, et al. Patient study of in vivo verification of beam delivery and range, using positron emission tomography and computed tomography imaging after proton therapy. *Int J Radiat Oncol Biol Phys* 2007;68:920-34.
- Heaton JM. The distribution of brown adipose tissue in the human. *J Anat* 1972;112:35-9.
- Ross R, Léger L, Guardo R, De Guise J, Pike BG. Adipose tissue volume measured by magnetic resonance imaging and computerized tomography in rats. *J Appl Physiol* 1991;70:2164-72.
- Gelfand MJ, O'Hara SM, Curtwright LA, Maclean JR. Pre-medication to block [(18)F]FDG uptake in the brown adipose tissue of pediatric and adolescent patients. *Pediatr Radiol* 2005;35:984-90.
- Parysow O, Mollerach AM, Jager V, Racioppi S, San Roman J, Gerbaudo VH. Low-dose oral propranolol could reduce brown adipose tissue F-18 FDG uptake in patients undergoing PET scans. *Clin Nucl Med* 2007;32:351-7.
- Himms-Hagen J. Obesity may be due to a malfunctioning of brown fat. *Can Med Assoc J* 1979;121:1361-4.
- Lowell BB, Flier JS. Brown adipose tissue, beta 3-adrenergic receptors, and obesity. *Annu Rev Med* 1997;48:307-16.
- Huttunen P, Hirvonen J, Kinnula V. The occurrence of brown adipose tissue in outdoor workers. *Eur J Appl Physiol Occup Physiol* 1981;46:339-45.
- English JT, Patel SK, Flanagan MJ. Association of pheochromocytomas with brown fat tumors. *Radiology* 1973;107:279-81.
- Nedergaard J, Bengtsson T, Cannon B. Unexpected evidence for active brown adipose tissue in adult humans. *Am J Physiol Endocrinol Metab* 2007;293:E444-E452.
- Rothwell NJ, Stock MJ. A role for brown adipose tissue in diet-induced thermogenesis. *Nature* 1979;281:31-5.
- Garruti G, Ricquier D. Analysis of uncoupling protein and its mRNA in adipose tissue deposits of adult humans. *Int J Obes Relat Metab Disord* 1992;16:383-90.
- Fukuchi K, Tatsumi M, Ishida Y, Oku N, Hatazawa J, Wahl RL. Radionuclide imaging metabolic activity of brown adipose tissue in a patient with pheochromocytoma. *Exp Clin Endocrinol Diabetes* 2004;112:601-3.
- Baba S, Engles JM, Huso DL, Ishimori T, Wahl RL. Comparison of uptake of multiple clinical radiotracers into brown adipose tissue under cold-stimulated and nonstimulated conditions. *J Nucl Med* 2007;48:1715-23.
- Tatsumi M, Engles JM, Ishimori T, Nicely O, Cohade C, Wahl RL. Intense (18)F-FDG uptake in brown fat can be reduced pharmacologically. *J Nucl Med* 2004;45:1189-93.
- Cinti S. The adipose organ. *Prostaglandins Leukot Essent Fatty Acids* 2005;73:9-15.
- Astrup A, Bülow J, Christensen NJ, Madsen J. Ephedrine-induced thermogenesis in man: no role for interscapular brown adipose tissue. *Clin Sci (Lond)* 1984;66:179-86.
- Gesta S, Tseng YH, Kahn CR. Developmental origin of fat: tracking obesity to its source. *Cell* 2007;131:242-56. [Erratum, *Cell* 2008;135:366.]
- Sharma AM, Pischon T, Hardt S, Kunz I, Luft FC. Hypothesis: beta-adrenergic receptor blockers and weight gain: a systematic analysis. *Hypertension* 2001;37:250-4.

Copyright © 2009 Massachusetts Medical Society.